



Concept note

Brain injury and SARS-CoV-2 infection: Bidirectional pathways

Hayder M. Al-Kuraishy^{1*}, Ali I. Al-Gareeb¹, Marta Chagas Monteiro² and Hanan J. Al-Saidy³

¹Department of Clinical Pharmacology, Medicine and Therapeutics, College of Medicine, Al-Mustansiriya University, P.O. Box 14132, Baghdad, Iraq.

²Department of Clinical Microbiology and Immunology, Faculty of Pharmacy, Federal University of Pará, Belém, Pará-66075-110, Brazil.

³College of Medicine, Al-Mustansiriya University, P.O. Box 14132, Baghdad, Iraq.

*Corresponding author. E-mail: hayderm36@yahoo.com; Phone: +96-407906230487

Article history

Received : October 04, 2020

Accepted : October 09, 2020

Keywords

CNS dysfunction
Coronavirus
COVID-19
SARS-CoV-2

ABSTRACT

Coronavirus infection disease (COVID-19) is a recent pandemic infectious disease caused by severe acute respiratory syndrome coronavirus (SARS-CoV-2). COVID-19 is associated with different neurological manifestations, as one-third of COVID-19 patients have some neurological disorders, including paraesthesia, headache, cold extremities and disturbances of consciousness, that are more evident in severely affected patients. The entry of SARS-CoV-2 into human host cells is mediated mainly by the cellular receptor angiotensin-converting enzyme 2 (ACE2), which is expressed at very low levels in the CNS under normal conditions. The dissemination of COVID-19 in the systemic circulation or across the cribriform plate of the ethmoid bone during an early or later phase of the infection can lead to cerebral involvement as has been reported in the past for SARS-CoV affected patients. COVID-19-related CNS dysfunction results from direct viral injury, indirect consequences of immune-mediated disease, systemic effects of infection, or local effects of the virus is still a matter of debate and these hypotheses are not mutually exclusive.

© 2020 Global SciTech Ocean Publishing Co. All rights reserved. ISSN. 2581-5008

INTRODUCTION

Coronavirus infection disease (COVID-19) is a recent pandemic infectious disease caused by severe acute respiratory syndrome novel coronavirus (SARS-CoV-2) (Fig. 1), first introduced in Wuhan, China that earlier known as Wuhan pneumonia. COVID-19 was declared by the World Health Organization (WHO) as a pandemic disease on March 11th, 2020. As of October 2020, there has been a total of 34,392,166 confirmed cases with 1,022,391 deaths globally (Al-Kuraishy et al., 2020a). The spike protein is the key structural protein which binds to host cell receptors to mediate virus invasion and determine viral tissue (Semwal et al., 2020).

COVID-19 AND NEUROLOGICAL DISORDERS

COVID-19 is associated with different neurological manifestations, as one-third of COVID-19 patients have some neurological disorders, including paraesthesia, headache, cold extremities and disturbances of consciousness, that

are more evident in severely affected patients. Also, SARS-CoV-2 may leads to viral encephalitis, brain oedema and neuronal degenerations (Al-Kuraishy et al., 2020b). In COVID-19, the neurological manifestations of infected patients have not been usually reported, since elderly patients that are commonly affected have altered level of consciousness, which might be confusing with the disturbances of patients with COVID-19. It has been reported that 6% of patients with COVID-19 presented with acute ischemic stroke, 15% with disturbances of consciousness and 19% with movement disorders (Al-Kuraishy et al., 2020c).

Viral infections have detrimental impacts on neurological functions, and even to cause severe neurological damage. Very recently, coronaviruses (CoVs), particularly SARS-CoV-2 display neurotropic properties and may also cause neurological diseases. It is reported that CoV can be found in the brain or cerebrospinal fluid (Al-Kuraishy et al., 2020d). The pathobiology of these neuroinvasive viruses is still incompletely known, and it is therefore important to explore the impact of CoV infections on the nervous system. Here, we

review the research into neurological complications in SARS-CoV-2 infections and the

possible mechanisms of damage to the nervous system.

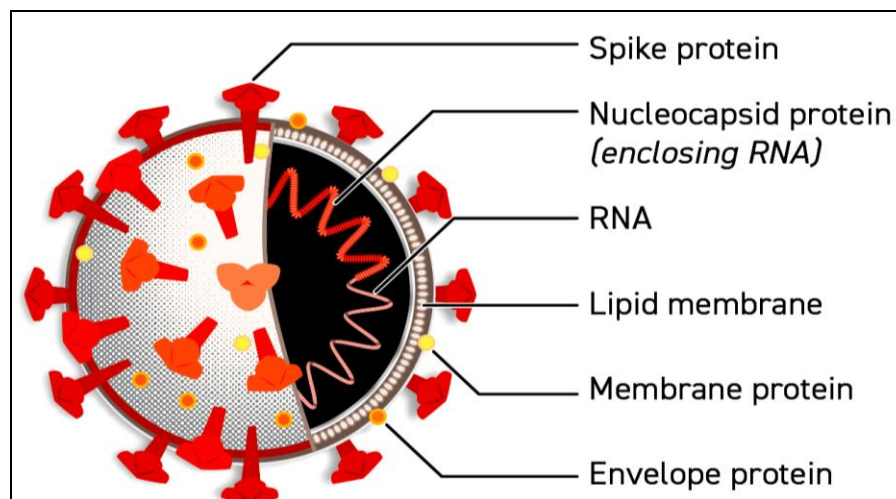


Fig. 1. Structure of SARS-CoV-2

Given the taxonomic similarity between SARS-CoV and SARS-CoV-2, it is plausible that patients with COVID-19 might also exhibit CNS damage related to the infecting coronavirus. It remains unclear to what extent SARS-CoV-2 can infect the CNS and, if it does, how the virus reaches the brain, but the possible theories have emerged: spread across the cribriform plate of the ethmoid bone in proximity to the olfactory bulb in patients at the early stage of the disease, resulting in the relatively common loss of sense of smell, or a later-occurring hematogenous spread on the setting of accompanied hypoxia, respiratory, and metabolic acidosis. Direct CNS infection by SARS-CoV has also been shown in mice, but whether SARS-CoV-2 infects the brain of humans remains unknown (Al-Kuraishy et al., 2020a).

PATHOGENESIS

The pathogenesis of these CNS effects of COVID-19 is not known, although direct invasion of the virus may be unlikely. The entry of SARS-CoV-2 into human host cells is mediated mainly by the cellular receptor angiotensin-converting enzyme 2 (ACE2), which is expressed at very low levels in the CNS under normal conditions (Al-Kuraishy and Al-Gareeb, 2020). CNS hypoxia due to respiratory failure caused by COVID-19, thrombotic microangiopathy, and an indirect effect of the vigorous inflammatory response with extensive cytokine activation that is commonly found in severe COVID-19 are more probable explanations, although further study is needed to examine these factors (Luostarinen et al., 2020).

POSSIBLE MECHANISM

Many authors have suggested that the virus enters the central nervous system (CNS) through olfactory neurons, as SARS-CoV-1 invades the

brains of mice brain in experimental models. This mode of entry could also explain the frequency of anosmia observed during the onset of COVID-19 (Fig. 2) (Kumar et al., 2020). However, after several months of a worldwide COVID-19 pandemic, there is no substantial evidence for the presence of SARS-CoV-2 in the brain, except for two patients with SARS-CoV-2, RNA detected in their cerebrospinal fluid (Paniz-Mondolfi et al., 2020).

If we assume that SARS-CoV-2 invades the brain through the olfactory pathway, the orbital prefrontal cortex, adjacent to the olfactory bulb, should be the first region of the brain affected. This hypothesis is supported by brain 18-fluoro-2-deoxy-D-glucose (18FDG) positron emission tomography-computed tomography (PET-CT) that showed hypometabolism within the orbitofrontal cortex in a COVID-19 patient with isolated anosmia (Kumar et al., 2020). Besides, another recent study found that 88.9% of electroencephalography (EEG) studies performed in COVID-19 patients for suspected encephalopathy and/or seizure-like events revealed epileptiform discharges, mostly within the frontal lobes (Galanopoulou et al., 2020).

The dissemination of COVID-19 in the systemic circulation or across the cribriform plate of the ethmoid bone during an early or later phase of the infection can lead to cerebral involvement as has been reported in the past for SARS-CoV affected patients. The presence of the COVID-19 virus in the general circulation understandably enables it to pass into the cerebral circulation where the sluggish movement of the blood within the microcirculation could be one of the factors that may facilitate the interaction of the COVID-19 virus spike protein with ACE2 expressed in the capillary endothelium (Montalvan et al., 2020). Subsequent budding of the viral particles from the capillary endothelium and damage to the endothelial lining can favour viral access to the brain. Once within the

milieu of the neuronal tissues, its interaction with ACE2 receptors expressed in neurons can initiate a cycle of viral budding accompanied by neuronal

damage without substantial inflammation as has been seen with cases of SARS-CoV in the past (Chougar et al., 2020).

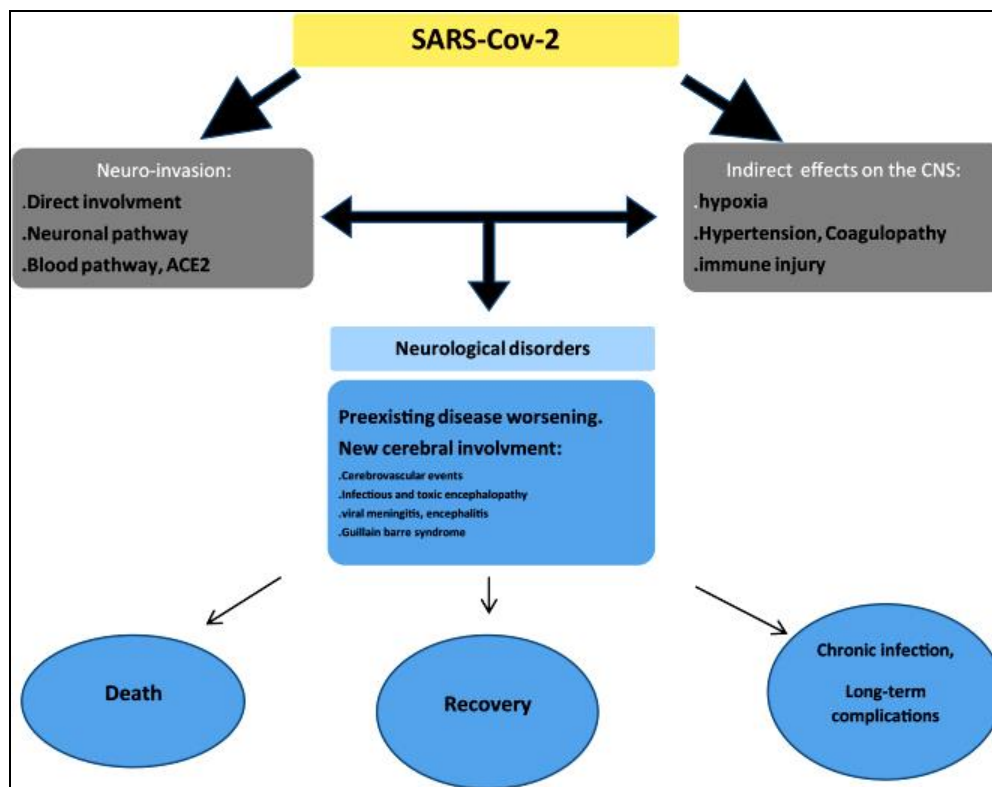


Fig. 2. Pathways and outcomes of brain SARS-CoV-2 infection

According to our cell-type distribution analysis, nuclear expression of ACE2 was found in many neurons (both excitatory and inhibitory neurons) and some non-neuron cells (mainly astrocytes, oligodendrocytes and endothelial cells) in human middle temporal gyrus and posterior cingulate cortex. A few ACE2-expressing nuclei were found in a hippocampal dataset, and none were detected in the prefrontal cortex. Except for the additional high expression of ACE2 in the olfactory bulb areas for spatial distribution as well as in the pericytes and endothelial cells for cell-type distribution, the distribution of ACE2 in mouse brain was similar to that in the human brain (Ma et al., 2020).

It is important to mention here that, long before the proposed anticipated neuronal damages occur, the endothelial ruptures in cerebral capillaries accompanied by bleeding within the cerebral tissue can have fatal consequences in patients with COVID-19 infections (Winkler et al., 2020). The movement of the COVID-19 virus to the brain via the cribriform plate close to the olfactory bulb can be an additional pathway that could enable the virus to reach and affect the brain. Additionally, the findings like an altered sense of smell or hyposmia in an uncomplicated early-stage COVID19 patient should be investigated thoroughly for CNS involvement. Autopsies of the COVID-19 patients, detailed neurological investigation, and attempts to isolate SARS-CoV-2 from the endothelium of cerebral microcirculation, cerebrospinal fluid, glial

cells, and neuronal tissue can clarify the role played by this novel COVID-19 causing coronavirus in the ongoing mortalities as has been in the recent outbreak (Vadhan and Speth, 2020).

Although the cerebral damage may complicate a COVID-19 infection, it appears that it is the widespread dysregulation of homeostasis caused by pulmonary, renal, cardiac, and circulatory damage that proves fatal in COVID-19 patients. With that being said, a dominant cerebral involvement alone with the potential of causing cerebral oedema in COVID-19 can take a lead in causing death long before systemic homeostatic dysregulation sets in (Paterson et al., 2020). Access of the COVID-19 virus to the brain via the transcribrial route could have been the case in a recently reported patient with hyposmia and the cases of acute respiratory failure in COVID19, which needs to be further elucidated by isolating the SARS-CoV-2 virus from the zones that are in proximity to the olfactory bulb (Agarwal et al., 2020).

CONCLUDING REMARKS AND PERSPECTIVES

It is expected that the differences in the sequence of spike proteins between COVID-19 virus and SARS-CoV will enable scientists to identify epitopes in CoV-2 for the development of monoclonal antibodies against this virus. With the recent COVID-19 outbreak, there is an urgent need

to understand the neurotropic potential of the COVID-19 virus to prioritize and individualize the treatment protocols based on the severity of the disease and predominant organ involvement. Also, a staging system based on the severity and organ involvement is needed in COVID-19 to rank the patients for aggressive or conventional treatment modalities (Reichard et al., 2020).

Therefore, whether COVID-19-related CNS dysfunction results from direct viral injury, indirect consequences of immune-mediated disease, systemic effects of infection, or local effects of the virus is still a matter of debate and these hypotheses are not mutually exclusive. However, the recent reports of frontal hypometabolism on PET-CT, frontal EEG abnormalities during COVID-19 and our case description are strong arguments in favour of a “SARS-CoV-2-related-frontal involvement” whether direct or indirect (Aghagoli et al., 2020).

In the light of the substantial body of evidence, this concept note explores and shed light on the potential direct or indirect effect of SARS-CoV-2 on the CNS in patients with COVID-19 pneumonia.

CONFLICT OF INTEREST

The authors declare no conflicts of interest.

REFERENCES

- Agarwal S, Jain R, Dogra S, Krieger P, Lewis A, Nguyen V, Melmed K, Galetta S (2020). Cerebral Microbleeds and Leukoencephalopathy in Critically Ill Patients With COVID-19. *Stroke*, 51, 2649-2655.
- Aghagoli G, Gallo Marin B, Katchur NJ, Chaves-Sell F, Asaad WF, Murphy SA (2020). Neurological Involvement in COVID-19 and Potential Mechanisms: A Review. *Neurocritical Care* [Epub ahead of print]. doi:10.1007/s12028-020-01049-4
- Al-Kuraishy HM, Al-gareeb AI (2020). From SARS-CoV to nCoV-2019: Ruction and argument. *Archives of Clinical Infectious Diseases*, 15, e102624.
- Al-Kuraishy HM, Al-Maiahy TJ, Al-Gareeb AI, Musa RA, Ali ZH (2020b). COVID-19 pneumonia in an Iraqi pregnant woman with preterm delivery. *Asian Pacific Journal of Reproduction* [Epub ahead of print]. Online available at <http://www.apjr.net/preprintarticle.asp?id=282984>
- Al-Kuraishy HM, Al-Naimi MS, Lungnier, CM, Al-Gareeb AI (2020d). Macrolides and COVID-19: An optimum premise. *Biomedical and Biotechnology Research Journal*, 4, 189-199.
- Al-Kuraishy HM, Al-Niemi MS, Hussain NR, Al-Gareeb AI, Al-Harchan NA, Al-Kurashi AH (2020c). The potential role of renin angiotensin system (RAS) and dipeptidyl peptidase-4 (DPP-4) in COVID-19: Navigating the uncharted. In: Selected chapters from the renin-angiotensin system, Kibel A (Ed). IntechOpen, London, pp. 151-165.
- Al-Kuraishy HM, Hussien NR, Al-Naimi MS, Al-Buhadily AK, Al-Gareeb AI, Lungnier CM (2020a). Is ivermectin-azithromycin combination the next step for COVID-19? *Biomedical and Biotechnology Research Journal*, 4, S101-103.
- Al-Kuraishy HM, Hussien NR, Al-Naimil MS, Al-Buhadily AK, Al-Gareeb AI, Lungnier C (2020e). Renin-Angiotensin system and fibrinolytic pathway in COVID-19: One-way skepticism. *Biomedical and Biotechnology Research Journal*, 4, S33-40
- Chougar L, Shor N, Weiss N, Galanaud D, Leclercq D, Mathon B, Belkacem S, Stroër S, Burrel S, Boutolleau D, Demoule A, Rosso C, Delorme C, Seilhean D, Dormont D, Morawiec E, Raux M, Demeret S, Gerber S, Trunet S, Similowski T, Degos V, Rufat P, Corvol JC, Lehericy S, Pyatigorskaya N; CoCo Neurosciences study group (2020). Retrospective Observational Study of Brain Magnetic Resonance Imaging Findings in Patients with Acute SARS-CoV-2 Infection and Neurological Manifestations. *Radiology* [Epub ahead of print]. doi: 10.1148/radiol.2020202422.
- Galanopoulou AS, Ferastraoaru V, Correa DJ, Cherian K, Duberstein S, Gursky J, Hanumanthu R, Hung C, Molinero I, Khodakivska O, Legatt AD, Patel P, Rosengard J, Rubens E, Sugrue W, Yozawitz E, Mehler MF, Ballaban-Gil K, Haut SR, Moshé SL, Boro A (2020). EEG findings in acutely ill patients investigated for SARS-CoV-2/COVID-19: A small case series preliminary report. *Epilepsia Open*, 5, 314-324.
- Kumar A, Pareek V, Prasoon P, Faiq MA, Kumar P, Kumari C, Narayan RK (2020). Possible routes of SARS-CoV-2 invasion in brain: In context of neurological symptoms in COVID-19 patients. *Journal of Neuroscience Research* [Epub ahead of print]. doi: 10.1002/jnr.24717.
- Luostarinen T, Virta J, Satopää J, Bäcklund M, Kivisaari R, Korja M, Raj R (2020). Intensive care of traumatic brain injury and aneurysmal subarachnoid hemorrhage in Helsinki during the Covid-19 pandemic. *Acta Neurochirurgica* [Epub ahead of print]. doi: 10.1007/s00701-020-04583-4.
- Ma A, Gao L, Wafi AM, Yu L, Rudebush T, Zhou W, Zucker IH (2020). Overexpression of Central ACE2 (Angiotensin-Converting Enzyme 2) Attenuates the Pressor Response to Chronic Central Infusion of Ang II (Angiotensin II): A Potential Role for Nrf2 (Nuclear Factor [Erythroid-Derived 2]-Like 2). *Hypertension* [Epub ahead of print]. doi: 10.1161/HYPERTENSIONAHA.120.15681.
- Montalvan V, Lee J, Bueso T, De Toledo J, Rivas K (2020). Neurological manifestations of COVID-19 and other coronavirus infections: A systematic review. *Clinical Neurology and Neurosurgery*, 194, 105921.
- Paniz-Mondolfi A, Bryce C, Grimes Z, Gordon RE, Reidy J, Lednický J, Sordillo EM, Fowkes M (2020). Central nervous system involvement by severe acute respiratory syndrome coronavirus-2 (SARS-CoV-2). *Journal of Medical Virology*, 92, 699-702.
- Paterson RW, Brown RL, Benjamin L, Nortley R, Wiethoff S, Bharucha T, Jayaseelan DL, Kumar G, Raftopoulos RE, Zambreau L, Vivekanandam V, Khoo A, Geraldes R, Chinthapalli K, Boyd E, Tuzlali H, Price G, Christofi G, Morrow J, McNamara P, McLoughlin B, Lim ST, Mehta PR, Levee V, Keddie S, Yong W, Trip SA, Foulkes AJM, Hotton G, Miller TD, Everitt AD, Carswell C, Davies NWS, Yoong M, Attwell D, Sreedharan J, Silber E, Schott JM, Chandratheva A, Perry RJ, Simister R, Checkley A, Longley N, Farmer SF, Carletti F, Houlihan C, Thom M, Lunn MP, Spillane J, Howard R, Vincent A, Werring DJ, Hoskote C, Jäger HR, Manji H, Zandi MS; UCL Queen Square National Hospital for Neurology and Neurosurgery COVID-19 Study Group (2020). The emerging spectrum of COVID-19 neurology: clinical, radiological and laboratory

- findings. *Brain* [Epub ahead of print]. doi: 10.1093/brain/awaa240.
- Reichard RR, Kashani KB, Boire NA, Constantopoulos E, Guo Y, Lucchinetti CF (2020). Neuropathology of COVID-19: a spectrum of vascular and acute disseminated encephalomyelitis (ADEM)-like pathology. *Acta Neuropathologica*, 140, 1-6.
- Semwal DK, Chauhan A, Semwal RB, Sircar D, Roy P, Lehmann J (2020). Natural molecules having anti-SARS-CoV activity – cannot they be effective against SARS-CoV-2? *Current Science*, 119, 757-770.
- Vadhan JD, Speth RC (2020). The role of the brain renin-angiotensin system (RAS) in mild traumatic brain injury (TBI). *Pharmacology & Therapeutics* [Epub ahead of print]. doi: 10.1016/j.pharmthera.2020.107684.
- Winkler ES, Bailey AL, Kafai NM, Nair S, McCune BT, Yu J, Fox JM, Chen RE, Earnest JT, Keeler SP, Ritter JH, Kang LI, Dort S, Robichaud A, Head R, Holtzman MJ, Diamond MS (2020). SARS-CoV-2 infection of human ACE2-transgenic mice causes severe lung inflammation and impaired function. *Nature Immunology* [Epub ahead of print]. doi: 10.1038/s41590-020-0778-2.

How to cite this article?

Al-Kuraishy HM, Al-Gareeb AI, Monteiro MC, Al-Saidy HJ (2020). Brain injury and SARS-CoV-2 infection: Bidirectional pathways. *Current Medical and Drug Research*, 4 (2), Article ID 207.
